



**PRESENTING CLINICAL SIGNS**

History: Chronic cough. Radiographs show cardiac enlargement vs. mass. No murmur.

**DATE**

5/25/22

**ECHOCARDIOGRAPHIC FINDINGS**

2D, M-mode, and Doppler study.

**PERFORMED BY:**

Tom McNeil

Left atrial size is normal. The mitral valve appears normal. Left ventricular dimensions are normal. Left ventricular systolic function is hyperdynamic. The aorta and aortic valve are normal. Right atrial and right ventricular dimensions are normal. The tricuspid valve appears normal. The pulmonary artery and pulmonic are normal. No shunting lesions are visualized. No pericardial effusion or cardiac masses are seen.

**INTERPRETED BY**

Keith Blass, DVM,  
MS, DACVIM  
(Cardiology)

LA - 19.6 mm  
LVIDd - 18.5 mm  
LVIDs - 9.6 mm  
FS - 48%  
LVOT - 0.77 m/s  
RVOT - 0.74 m/s

**PATIENT**

Chicken Shaw

**ASSESSMENT/RECOMMENDATIONS**

Normal echocardiogram

**SPECIES**

Canine

This examination demonstrates no evidence of structural heart disease. As such, Chicken's cough does not appear to be cardiogenic in origin. While a definitive reason for the cough is not appreciated in Chicken's radiographs, dynamic tracheal collapse and inflammatory airway disease should be considered as likely differentials.

**BREED**

Chihuahua

No therapy is recommended based on this exam.

A recheck echocardiogram is recommended if new physical exam and/or clinical abnormalities suggestive of cardiac dysfunction develop.

**SEX**

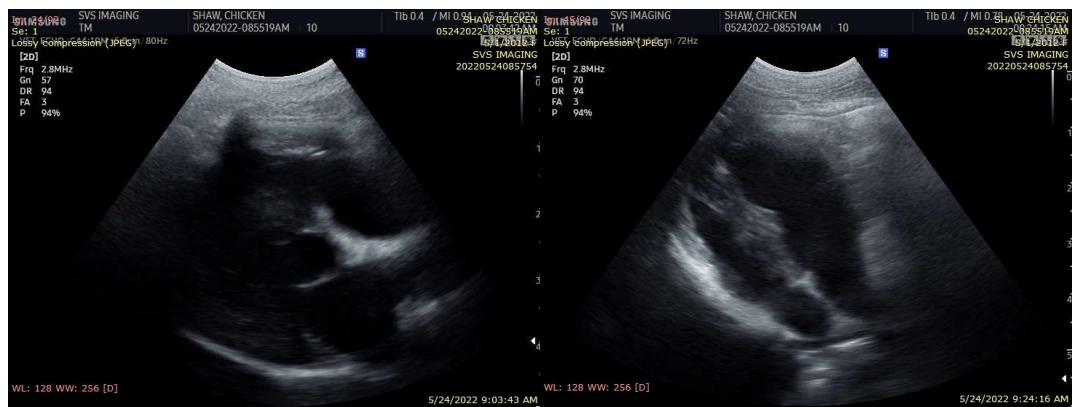
FS

**AGE**

10 y

**WEIGHT**

6.8 lb



**HOSPITAL NAME**

SVS Imaging CT

The information and recommendations provided are based on the images presented by the referring veterinarian. No evaluation can be communicated regarding pathology that was not visible in the image/video clips provided.

**REFERRING VET**

Dr. Perkins

Thank you for this referral. If the clinical or image interpretation does not parallel your findings or



if I can be of any further assistance please contact me.

**DATE**

5/25/22

**Keith Blass, DVM, MS, DACVIM (Cardiology)**

KeithBlass@gmail.com

631-804-5754

**PERFORMED BY:**

Tom McNeil

**INTERPRETED BY**

Keith Blass, DVM,

MS, DACVIM

(Cardiology)

**PATIENT**

Chicken Shaw

**SPECIES**

Canine

**BREED**

Chihuahua

**SEX**

FS

**AGE**

10 y

**WEIGHT**

6.8 lb

**HOSPITAL NAME**

SVS Imaging CT

**REFERRING VET**

Dr. Perkins